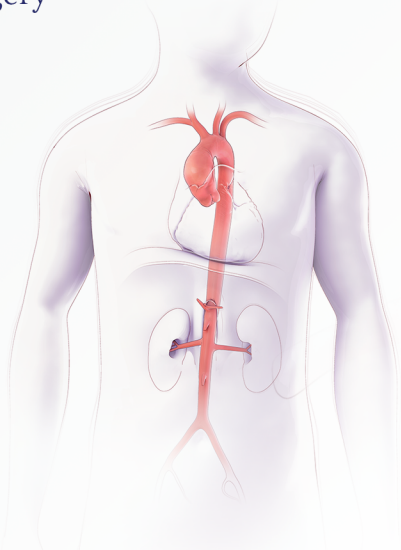
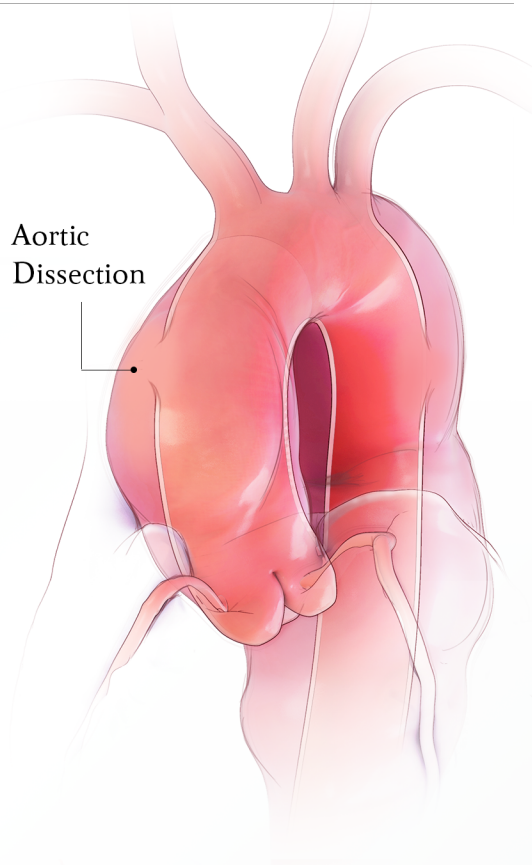


Type A Aortic Dissection Hybrid Repair with Frozen Elephant Trunk (with Aortic Valve Resuspension, Hemiarch Reconstruction, and Descending Stent Graft)

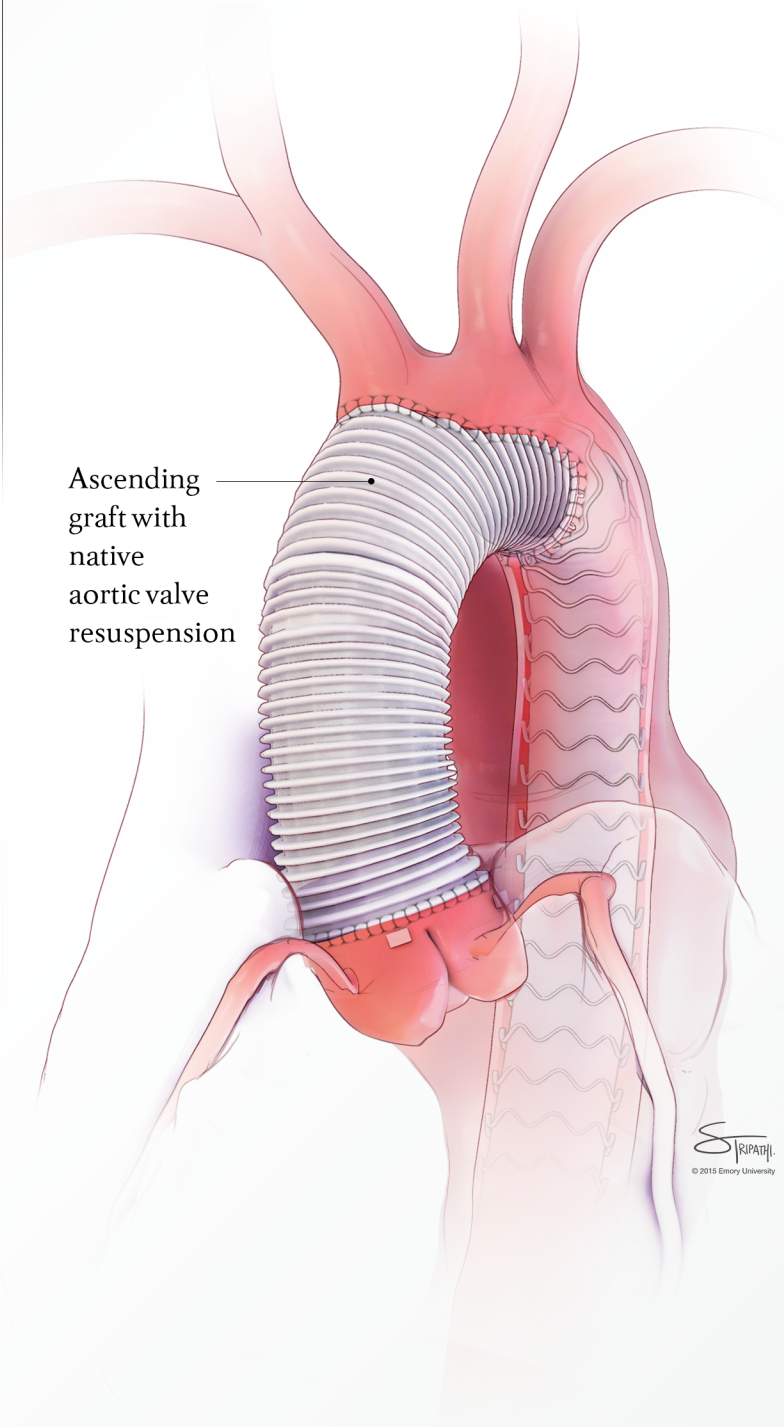
Before surgery



Close-up of diseased aorta



After surgery



STRIPATH  
© 2015 Emory University