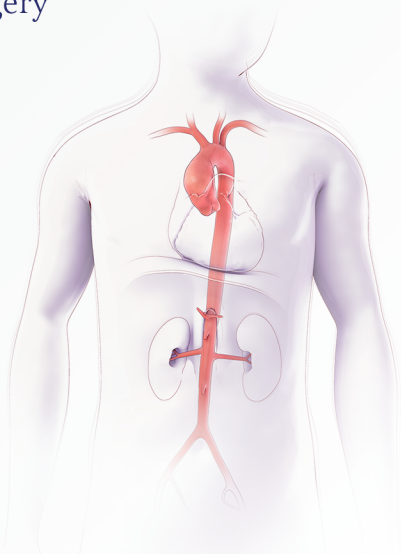
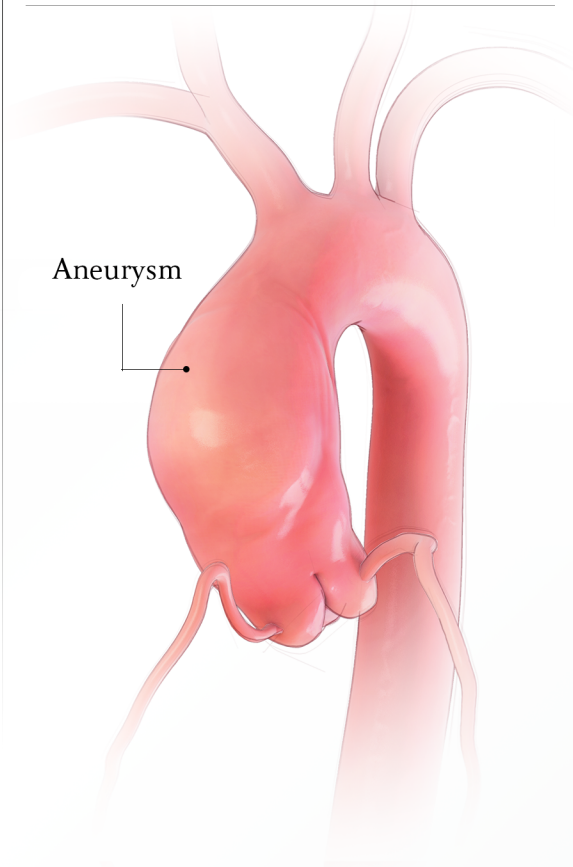


Tissue Valved Conduit Repair

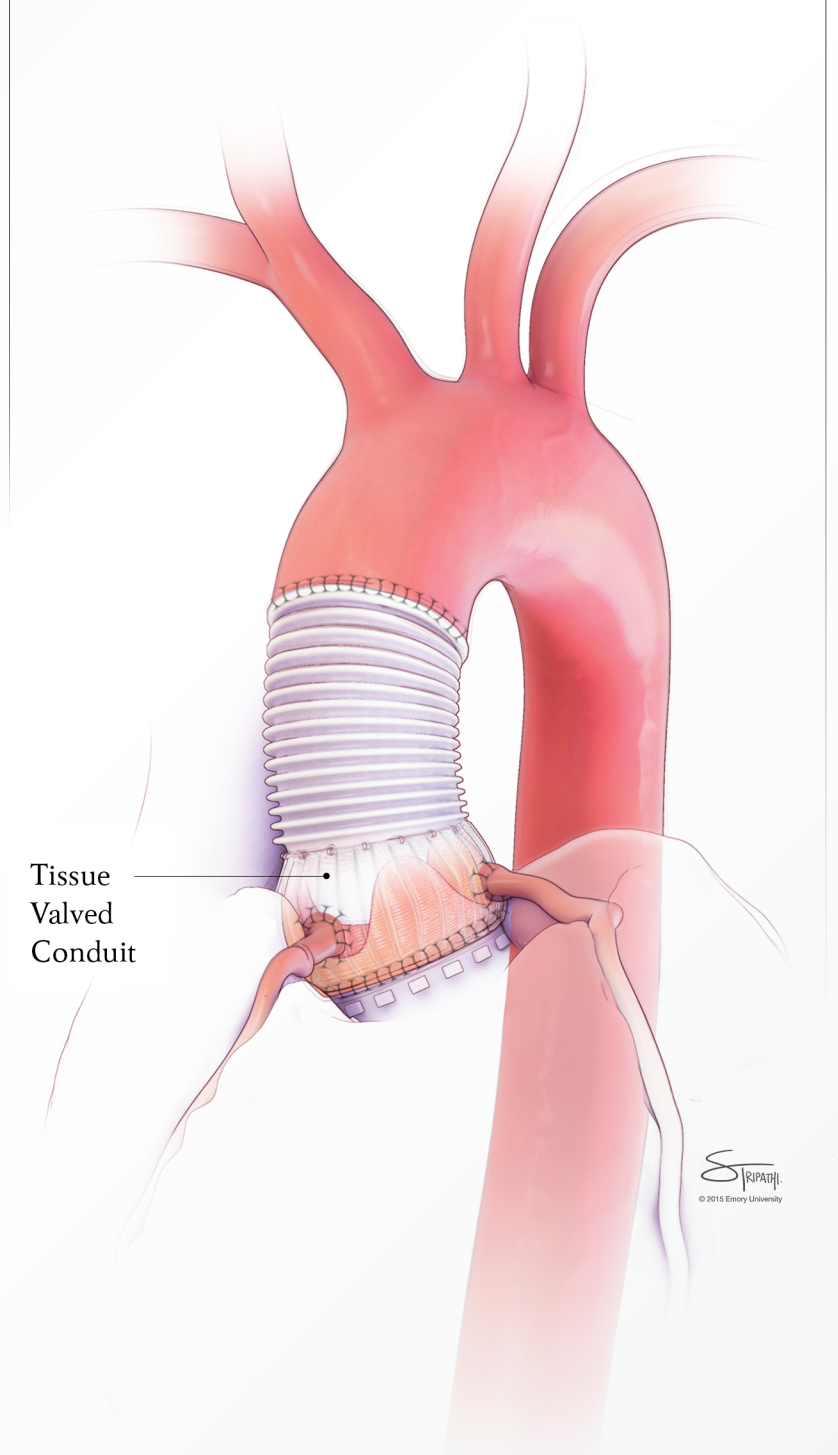
Before surgery



Close-up of diseased aorta



After surgery




© 2015 Emory University