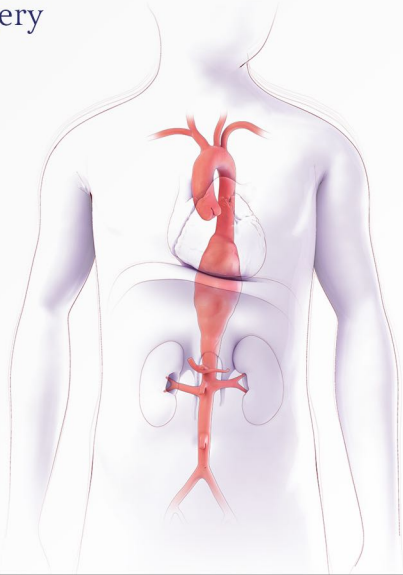
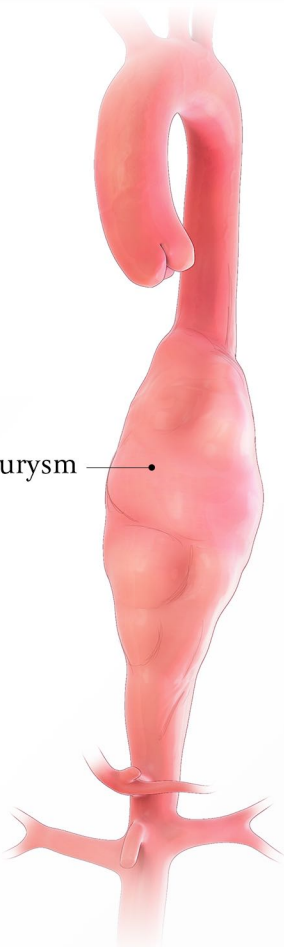


Descending Aortic Stent Graft (TEVAR) - Extent B

Before surgery



Close-up of diseased aorta



After surgery

